

CLEFT LIP SURGERY

a practical guide

© 2008 Bart van de Ven, Joel Defrancq
Authors: Bart van de Ven, Joel Defrancq, Ellen Defrancq
Drawings: Karel van Rooijen
Lay-out: Ellen Defrancq
Printed by : Drukarna WIST, Zgierz, Poland

*All rights reserved. No part of this publication may be reproduced without permission of the authors.
Permission may be sought via the following e-mail: bart@agaveclinic.com.*

Notice:

Every effort has been taken to confirm the accuracy of the information presented. The authors can not be held responsible for errors or for any consequences arising from the use of the information contained herein.

CLEFT LIP SURGERY

a practical guide

AUTHORS: *Bart van de Ven*
Joel Defrancq
Ellen Defrancq

DRAWINGS: *Karel van Rooijen*

About the video

The 3 operations as described in this book you can see on video. You'll find the videos at **<http://www.agaveclinic.com/EN/cleft.php>**.

Bart van de Ven is the surgeon who performs the operations.

This video will surely help you, in combination with the book, to gain good insight in these operations. It is a perfect complement to the book as not everything can be easily described in words and static images.

Preface

The idea behind this book is to explain in simple and clear terminology how a primary lip closure in a cleft patient can be performed. There are of course many excellent and beautiful textbooks as well as articles on cleft surgery, but here you find one with simple straightforward guidelines. We included many pictures, drawings and pictures to approach the subject three dimensionally. The focus is on the illustrations and not on the text. The methods presented here are well founded and universally recognized, but other and different techniques can lead as well to outstanding results.

The way to go is to build a vast body of experience in performing those surgeries repetitively—strengthened by a systematic and strong methodology. If you follow this book step by step, you have a framework to perform the surgery and the results will be very acceptable. Of course, postoperative results will improve with more experience. All of us, once, had to assimilate those surgical skills. It took time, discussion and growing maturity, and... it did not happen over night.

We hope this booklet can help you to improve your results over time and bring you to a point of confidence and no operational stress. There is still a great demand for people that can perform those surgeries, especially in developing countries. This booklet can be your guide and your rewarding friend.

BART VAN DE VEN, Marbella, Spain

JOEL DEFRANCO, Antwerp, Belgium


 *Maxillofacial Surgeons*

Table of contents

Anatomy Cleft lip 10

Some practical tips 12

Use of Methylene blue for the landmarks	12
Suturing material	13

Unilateral Cleft lip 14

Introduction 14

Tennison-Randall procedure	15
Millard procedure	16
The choice	17

Tennison-Randall procedure 20

LANDMARKS 22

Nasal landmarks	23
Vermillion border landmarks	24
Skin triangle landmarks	25
Mucosal triangle landmarks	27
Vestibular landmarks	29
Infiltration	30
Cutting design	30

CUTTING 32

Cutting of the mucosal and cutaneous tissues	32
Cutting for the Basket-Weave Muscle Repair	34
Undermining of the alar base area	36

SUTURING 37

Try-in of the suture for the alar base positioning	37
Vestibular suturing	39

Nasal floor suturing	40
Alar base suturing	40
Basket-weave muscle suturing	41
Caudal muscle layer suturing	43
Final closure suturing	44
Silastic sheet suturing	45

Unilateral Millard Procedure 46

INTRODUCTION 46

LANDMARKS 48

Nasal landmarks	48
Vermillion border landmarks	49
Landmarks for the rotational and advancement flap	50
Mucosal triangle landmarks	52
Infiltration	54
Cutting design	54

CUTTING 56

Cutting of the mucosal and cutaneous tissues	56
Cutting for the Basket-Weave Muscle Repair	57
Undermining of the alar base area	59

SUTURING 61

Try-in of the suture for the alar base positioning	61
Vestibular suturing	63
Nasal floor suturing	63
Alar base suturing	63
Basket-weave muscle suturing	63
Caudal muscle layer suturing	64
Final closure suturing	65
Silastic sheet suturing	66

Bilateral Millard procedure 68

LANDMARKS 70

Nasal landmarks	70
Vermillion border landmarks	71
Mucosal triangle landmarks	72
Vestibular landmarks	73
Infiltration	74
Cutting design	74

CUTTING 76

Cutting of the mucosal and cutaneous tissues	76
Cutting for the Basket-Weave Muscle Repair	77
Undermining of the alar base area	78

SUTURING 78

Try-in of the suture for the alar base positioning	78
Vestibular suturing	79
Nasal floor suturing	80
Alar base suturing	80
Basket-weave muscle suturing	81
Caudal muscle layer suturing	83
Final closure suturing	83
Silastic sheet suturing	85

About the instruments 86

About the authors 87

PART
1

Anatomy Cleft lip

Illustration 1:
Anatomy of the normal lip.




Illustration 2:
Anatomy of the unilateral cleft lip.

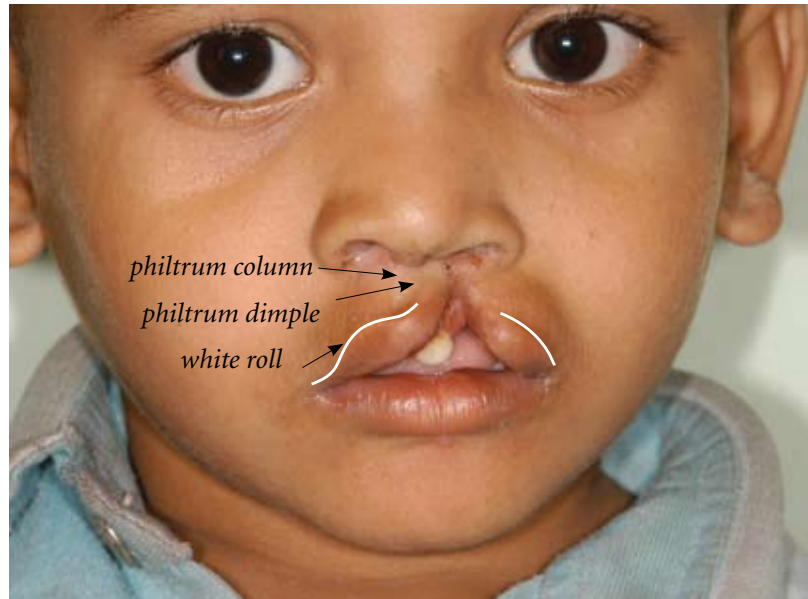
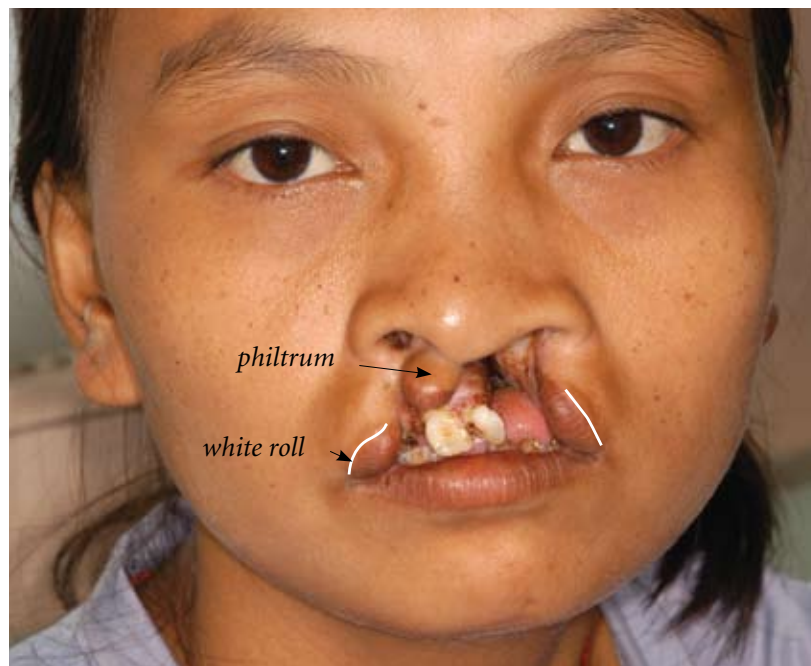

Illustration 3:
Anatomy of the bilateral cleft lip.
Notice that the philtrum doesn't have a dimple or a column because there is no muscle. Also the white roll is missing under the philtrum.



**PART
2**

Some practical tips

USE OF METHYLENE BLUE FOR THE LANDMARKS

We always start by marking a standard series of landmarks. Most people use methylene blue on a sharpened wood stick. Once you are sure the landmarks are in the right position, you can turn them in temporary tattoo landmarks with methylene blue on a needle tip.



Practical tip

First mark the points with a wood stick, sharpened and dipped in methylene blue. Then tattoo the landmark points with a 23 gauge needle tip. Dip the needle point in a 2cc syringe where only the very beginning is filled with a good quality of methylene blue. Tattoo the points with a repetitive fingertip rotating movement and almost no pressure. A bleeding point can indeed be very disturbing for your design.

If you go abroad, bring your own methylene blue since the quality abroad can be very disappointing.

SUTURING MATERIAL



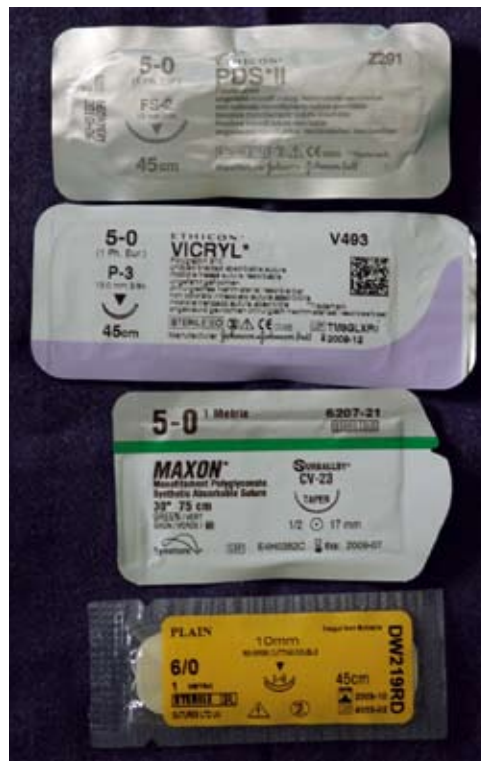Practical tip

For suturing we use the following material:

- *Positioning of the alar base of the nose:* PDS 5-0
- *Mucosa and subcutis:* vicryl 5-0
- *Muscle slings:* maxon 5-0
- *Skin:* catgut 6-0

Catgut has the advantage of being resorbable in 5-7 days. In Western countries however, its use is forbidden because of the mad-cow disease. In development countries you can still buy and use it.

If the necessary aftercare for suture removal is available, a nylon suture 6-0 can be used as well to close the skin.



Introduction

Two basic techniques are universally in use for unilateral cleft lip closure: the Tennison-Randall procedure and the Millard procedure. Both techniques recognize the importance of repositioning the lip muscle (orbicularis oris) in a correct anatomic orientation that results in an aesthetic as well as a functional improvement.

The popularity of the triangular flap technique (Tennison-Randall) diminished in the 1970 to 1980s with the gaining popularity of the Millard procedure. However the triangular flap again gained popularity with widespread practice in many highly regarded institutions. So, both techniques must be considered essential in the armamentarium of the cleft surgeon.

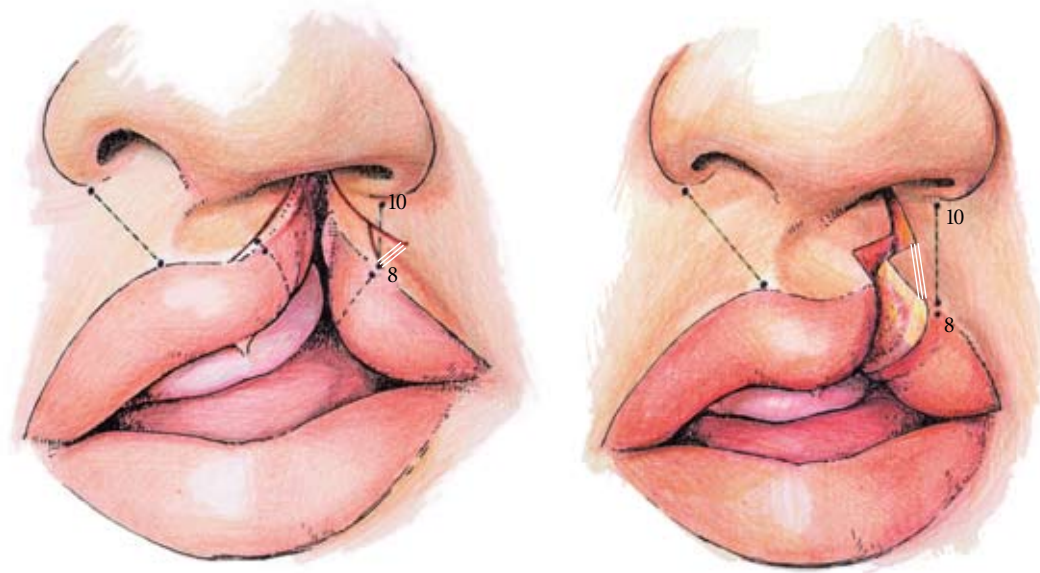
TENNISON-RANDALL PROCEDURE

The Tennison-Randall procedure is known as a geometrical design requiring exact pre-surgical measurements. Once the basic principles of cleft lip repair are fully understood the operation is fairly straightforward and should lead to pleasing surgical results. The operation is done strictly on mathematical principles and measurements. There is little room for surgical flexibility and artistry. This is most of the time and for most of us an advantage since errors in surgical artistic licence are common and never far away.

An important *advantage* of the Tennison-Randall procedure is the *lip lengthening effect* between the alar base and the Cupid's bow on the affected side (distance 8-10).

Illustration 4:

The lip lengthening effect of the Tennison-Randall procedure on the lateral side of the cleft.



The *disadvantage* however is the disturbance of the aesthetic unit of the CS philtrum column in the lower third. This is a violation of a known anatomic subunit, but not always that obvious. The philtrum dimple has a tendency to be more flat in the classical Tennison. This is no longer the case if the basket-weave method of interlacing the orbicular muscle is used.

MILLARD PROCEDURE

The Millard procedure is known as the rotation-advancement technique. It is a more flexible technique – cut as you go – but needs more experience and artistry.

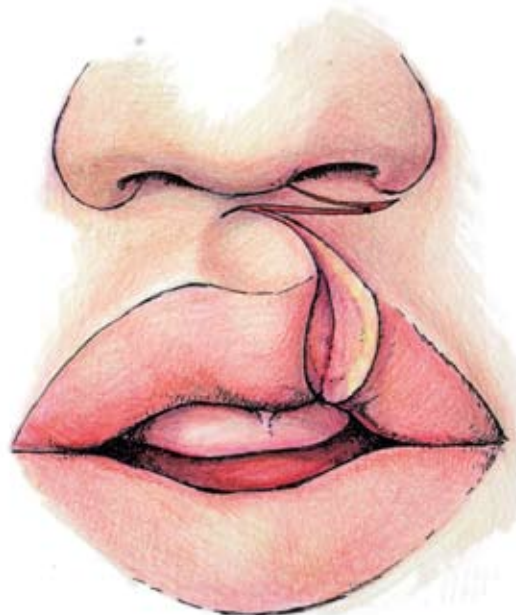The *advantage* of this technique is that it camouflages the violation of the philtrum column near the nose.

The *disadvantage* however is that one can easily get a vertical scar contracture with *vermilion notching of the lip* or *lowering of the alar base*. Horizontal scar contracture provokes a tendency towards a *small nostril*. Excessive narrowing of the nostril is never far from reality and the surgeon should simply aim for a slightly larger nostril on the cleft side.

In most articles you will find that pre-surgical measurements are less important in the Millard procedure. But small mistakes in judgement, even by excellent surgeons, can quickly translate into irreversible cosmetic concerns. Therefore we think that measurements are equally as important in the Millard technique as in the Tennison-Randall technique.

Illustration 5:

The Millard procedure just before the closing procedure.



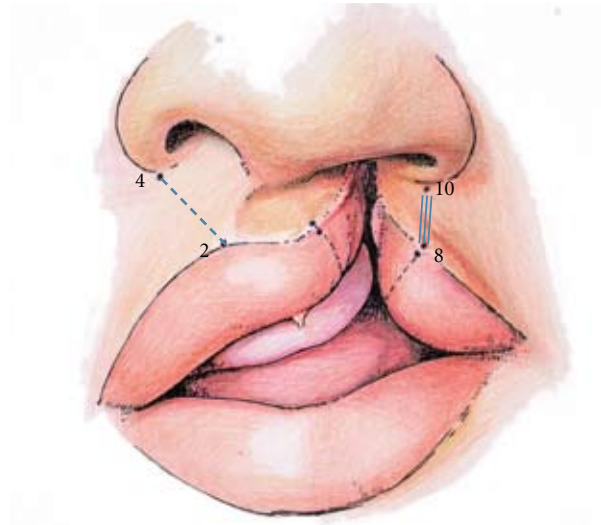
THE CHOICE

Roughly speaking, we use the Millard technique for the partial cleft and the Tennison-Randall for the wide open clefts.

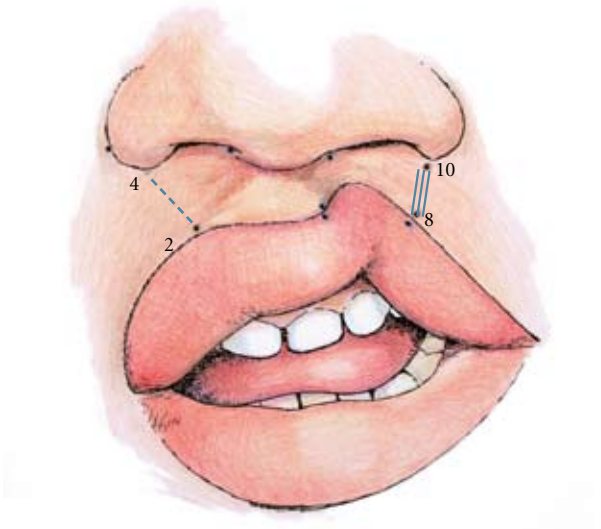
The ultimate decision comes from measuring the **distance between the alar base and the end of the white roll** on the cleft side (CS). Compare this distance with the non-cleft side (NCS). Most often you will see that the CS is smaller. *If the distance on the cleft side (8-10) is more than 2-3mm shorter than on the NCS (4-2), we use the Tennison-Randall technique. If it's less than 2 mm shorter, we use the Millard procedure.*

Illustration 6:

A wide open cleft lip, where a Tennison-Randall is recommended because the CS is more than 2 mm shorter.

**Illustration 7:**

A partial cleft, where a Millard procedure is recommended because the CS is less than 2 mm shorter.



The reason is as follows: if the **difference is more than 2-3 mm**—like in most *complete clefts*—you need to find a way to compensate because if the lengthening is not properly realized the operation will end up with *vertical discrepancies in the lip architecture* that catch attention right away.

The *Tennison-Randall* compensates by bringing in a triangle of extra tissue. The Millard lengthens the lip medial by straightening a curved incision. But laterally the lip is not lengthened. The alar base will be positioned too low, or the Cupid’s bow will be pulled up (*Lazarus DD and co.*; “*Repair of unilateral cleft lip: a comparison of five techniques*” in *ANN PLAST SURG*, 1998, DEC;41(6):587-94).

Illustration 8:

Alar base on the operated side (10) is too low after a Millard operation. A Tennison-Randall would have been a better choice.

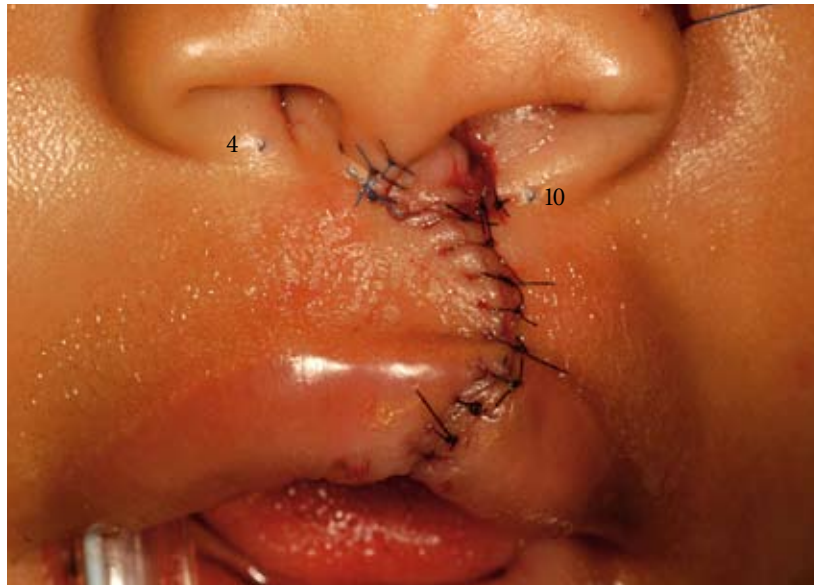
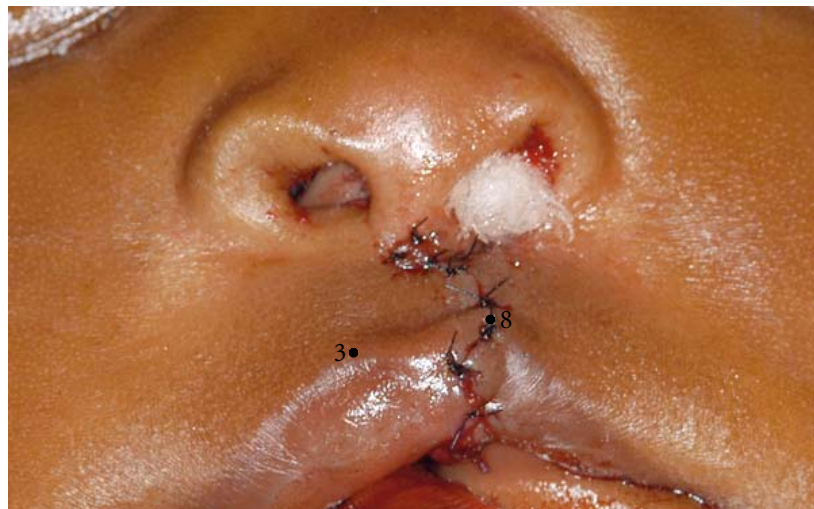

Illustration 9:

The Cupid’s bow is pulled upwards on the operated side after a Millard operation. A Tennison-Randall would have been a better choice.



In the *Millard* procedure, the only way to sail around is to place the end of the white roll on the CS (8) more laterally. This shortens the lip horizontally on the cleft side, but small differences in lip width do not show as obviously as even the most subtle asymmetry in the lip height. But there are aesthetical limits to how lateral one can go.

Sometimes however the **difference is less than 2-3 mm**—like in most *partial clefts*. The length of the alar base to the end of white roll is comparable to the other side, and sometimes even longer and more voluminous.

The *Tennison-Randall* technique then creates a too long lip on the affected side, since you bring in a triangle of extra tissue. The *Millard* technique perfectly suits these cases.

Tennison-Randall procedure

Illustration 10:
Cutting design for the Ten-
nison-Randall procedure.

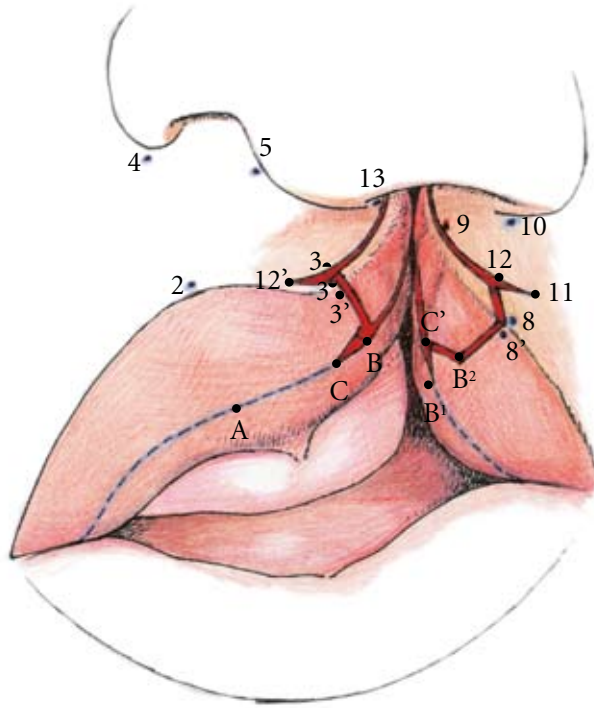


Illustration 11:
Tennison-Randall procedure after cutting.

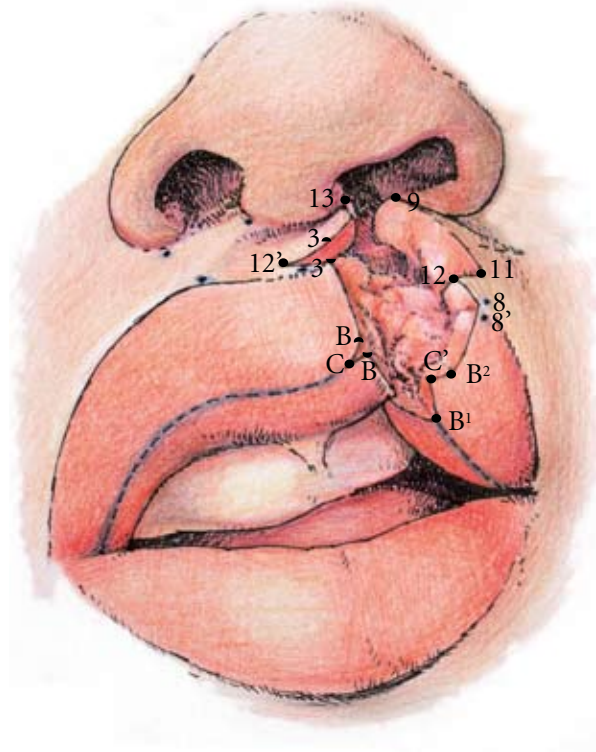
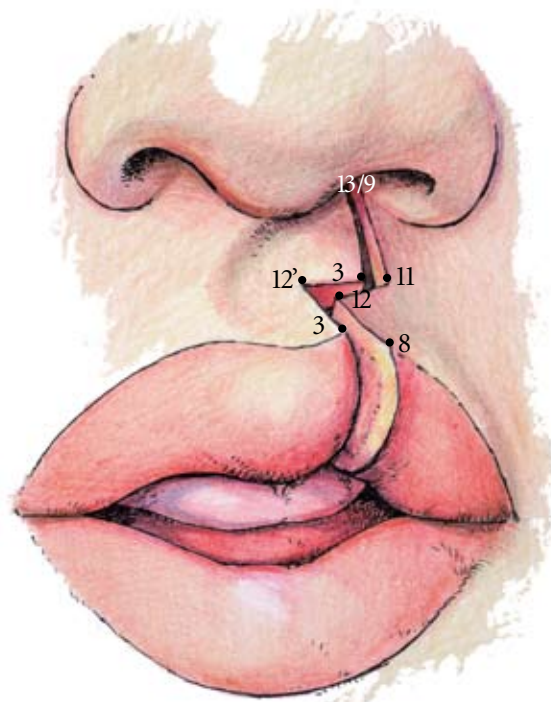


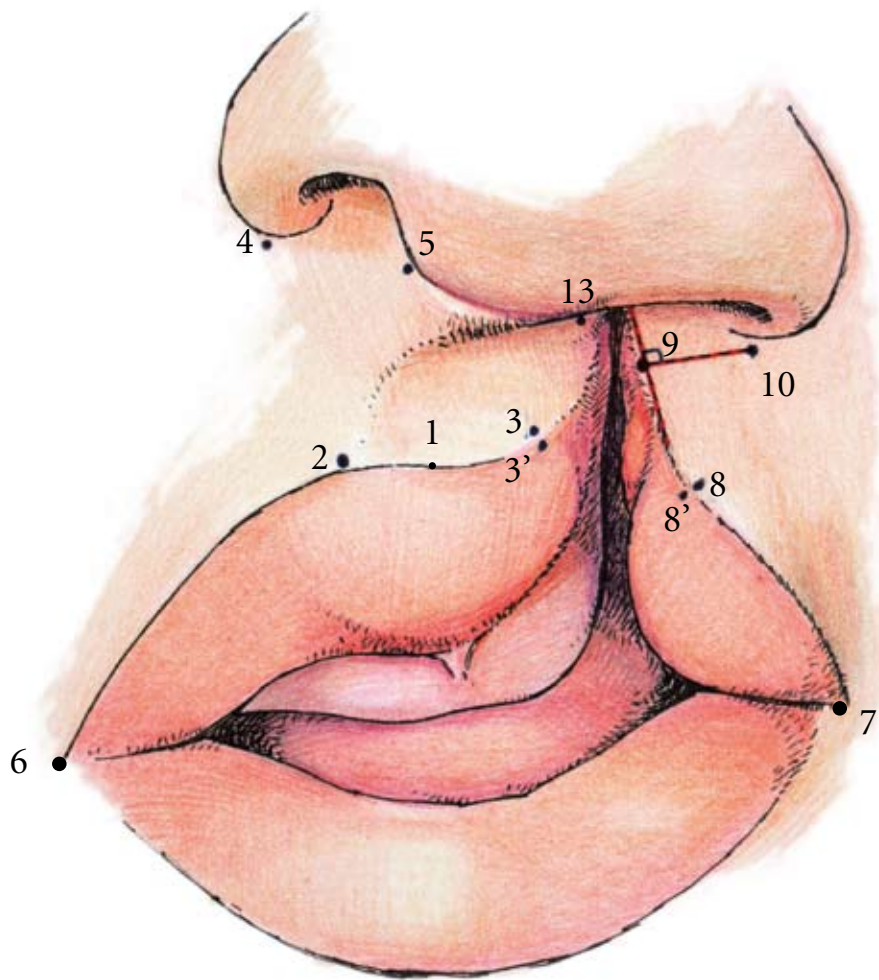
Illustration 12:
Tennison-Randall just before closure of the skin and mucosa.



LANDMARKS

Illustration 13:

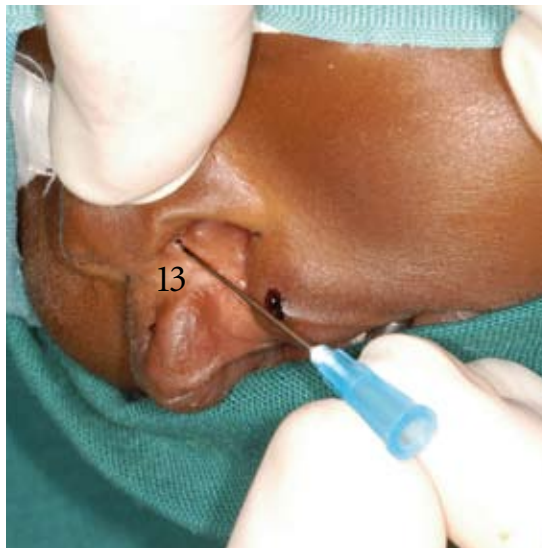Nasal and vermillion border landmarks for the Tennison-Randall design.



NASAL LANDMARKS

Landmark 5 and 13 First mark the end of the medial crus of the lower lateral cartilage. This landmark is considered the columellar base. The German name for this landmark is famous: 'Naseneingangschwelle'. This is landmark (5) on the non-cleft side and landmark (13) on the cleft side.

Illustration 14:
Marking landmark 13 at the end of the medial crus of the lower lateral cartilage.



Landmark 4 and 10 Mark the *alar bases* as landmarks (4) and (10). These landmarks are found at the end of the light reflection on the nostrils. It is most important that both landmarks are in a comparable position right to left, otherwise your measurements are meaningless.

These four landmarks are made close to the cartilage in order to allow for maximum rotation of the alar base.

VERMILLION BORDER LANDMARKS

Landmark 2, 3 and 1 Landmark (2) is the top of the Cupid's bow on the healthy side and is easy to locate. Therefore it is tattooed right away.

Landmark (3) is the end of the white roll on the NCS, it represents the other end of the Cupid's bow. Landmark 3 is tattooed as well.

Landmark (1) is chosen as the middle of (2) and (3). It represents the middle of the Cupid's bow.

Landmark 8 On the lateral or cleft side (CS) we still need to establish the peak of the Cupid's bow. This is landmark (8) and is the end of the white roll on the CS.

The distance between the commissure on the non-cleft side and the Cupid's bow landmark (6)-(2) is measured and transferred to the cleft side. Almost universally the available distance (7)-(8) is shorter. This gives an idea of the amount of shortening of the lip on the CS.



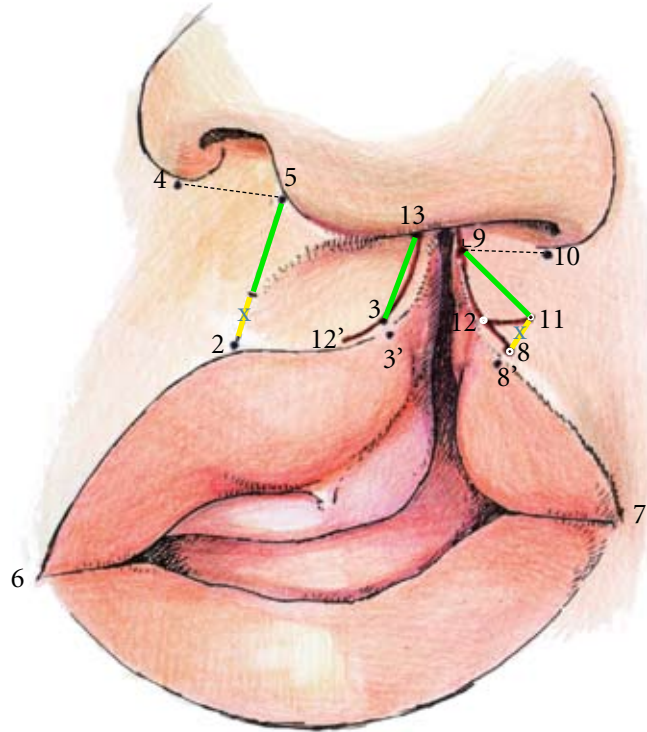
Note on landmark 8

Shorter means that the lip at the end of operation will be shorter on the CS. This is not so obvious or disturbing on first sight and tends to fade away during life. What on the other hand is obviously disturbing is a Cupid's bow too high or a nostril too low. This catches the attention right away.

Landmark 3' and 8' On both sides of the cleft landmarks (3) and (8) are the paring peaks of the Cupid's bow and they are marked twice: One landmark is marked just above the white roll (3 and 8) and one landmark is perpendicular to the white roll just in the red lip (3' and 8'). The distance between both upper and lower landmarks is on average 1,5 mm. It is most important that this little distance is equal on both sides. These four cardinal landmarks should stay clearly visible during the whole surgery. Suturing these landmarks at the end of the procedure will create the new Cupid's bow top with a close to normal white roll, in a continuous mode and without steps.

SKIN TRIANGLE LANDMARKS

Illustration 15:
Measurements for the tri-
angular design.



The distance from landmark (5) to (2) should finally become the lip length on the cleft-side too. Since length (13)-(3) is 'x' shorter than (5)-(2), 'x' must be added to establish equal length. We bring this in as a triangular skin flap from the cleft side with a base of 'x'.

This triangular skin flap, after incision, will be brought in via a deep incision from (3) to (12'), thus splitting (3). Later, the upper half of (3) will be sutured to (11), the lower half to (8). This reconstructs the lip with a normal contoured Cupid's bow and a zigzag scar line, which also prevents vertical scar contracture.

Landmark 11

Landmark (11) is situated at a distance 'x' from landmark (8) perpendicularly away from the white roll.